

ATS 2023 Highlights

Respiratory Structure and Function Early Career Professionals



David Mummy, Ph.D.

Assistant Professor
Department of Radiology
Duke University, Durham NC
david.mummy@duke.edu

Get to know members of the RSF Assembly

Is your research clinical, basic science or translational?

Translational

Tell us about your research

I study clinical applications of hyperpolarized Xenon-129 gas MRI in a range of lung diseases, including asthma, COPD, and ILDs. This inhaled contrast agent allows us to directly image Xenon in its gaseous form and then as it is absorbed into the alveolar membrane and then into the pulmonary capillaries, probing the lung microstructure to generate regional measurements of gas exchange. It's pretty cool!

Where do you see yourself in 5 years?

Xenon MRI is nearing a "tipping point" as it has recently been granted FDA approval and as we continue to establish clinical applications and lay groundwork for new sites to come online. I'm really excited to continue these efforts and help turn this technique into a tool clinicians can turn to for improving individual patient outcomes.

What do you find is the major benefit of RSF Assembly Membership?

RSF events and sessions provide an unparalleled opportunity to interact with researchers who approach many of the same kinds of questions as you do but from a wide variety of different angles. It's an invaluable way to make connections and get a fresh perspective on your research questions, challenges, and goals.



Please follow us on Twitter



@ATS_RSf

and like our Facebook



page!

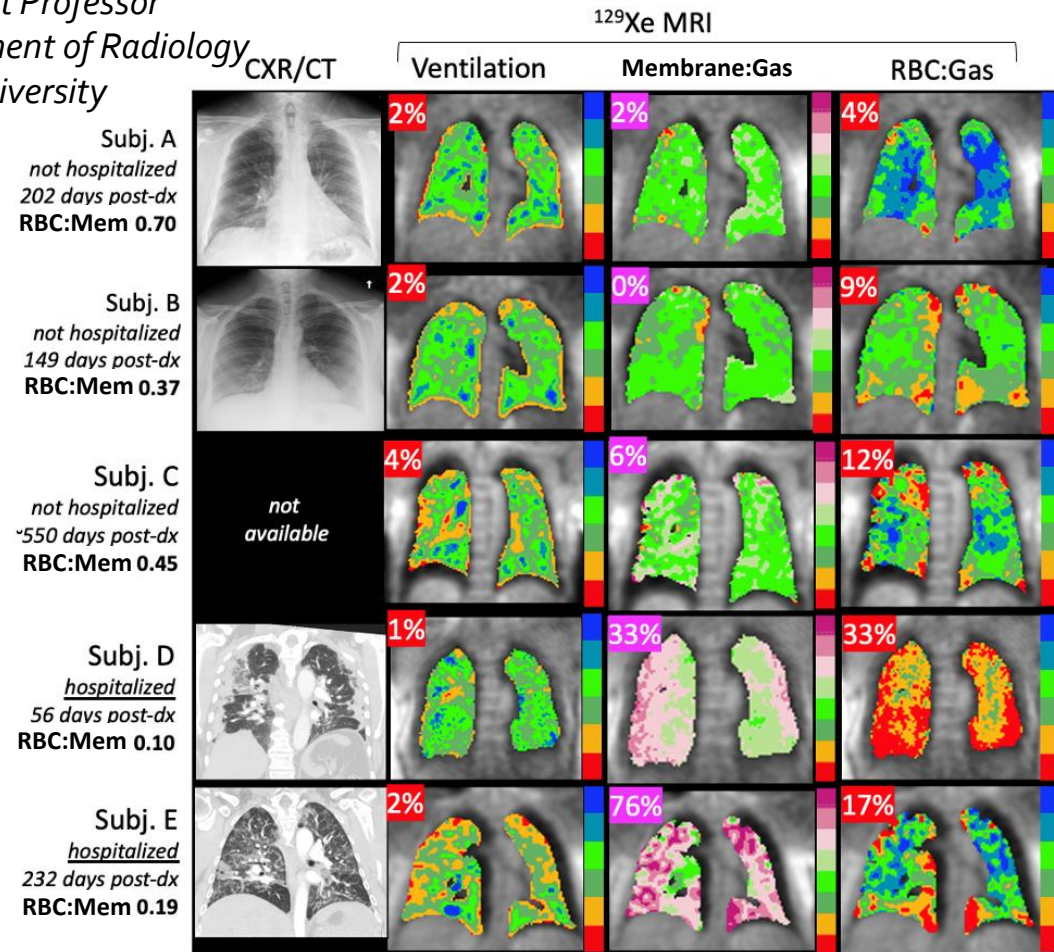
If you or someone you know would like to be featured as an ATS RSF ECP please email Katrina Tonga (katrina.tonga@sydney.edu.au)

ATS 2023 Highlights

Respiratory Structure and Function Early Career Professionals

David Mummy, Ph.D.

Assistant Professor
Department of Radiology
Duke University



Hyperpolarized ¹²⁹Xe MRI is sensitive to variations in gas exchange impairment in patients with long haul COVID-19

RATIONALE: Many patients who have recovered from COVID-19 have residual pulmonary disease in the form of persistent, disabling symptoms characterized as “long-haul COVID.” Here, we used hyperpolarized ¹²⁹Xe MRI to characterize the impact of long-haul COVID-19 on regional gas exchange function.

METHODS: Patients with persistent dyspnea > 50 days after initial COVID-19 diagnosis (N=5) underwent hyperpolarized ¹²⁹Xe MRI and spectroscopy. For each patient, signals from gas phase, interstitial membrane tissue uptake, and red blood cell [RBC] transfer were acquired during a single breath-hold. Functional image voxels were binned according to thresholds derived from a healthy reference cohort. The ratio of RBC to Membrane signal (RBC:Bar) was obtained from ¹²⁹Xe spectroscopy.

RESULTS: Ventilation was uniformly well preserved (Figure 1), however, high membrane percent varied widely. Most subjects exhibited some degree of RBC defect, as well as reduced RBC:Bar. Although all patients reported some combination of persistent dyspnea/fatigue, imaging reveals some to have significantly impaired gas exchange function while in others it was relatively preserved. Notably, the two patients with elevated high membrane percent were the only two patients who underwent hospitalization.

CONCLUSIONS: Long-haul COVID subjects with persistent chronic symptoms exhibited a variety of findings on ¹²⁹Xe MRI, ranging from apparently normal lung function to severe gas exchange impairment. In patients with persistent chronic symptoms where gas exchange abnormalities are determined to be a factor, ¹²⁹Xe MRI may be useful as a sensitive means of longitudinal monitoring and assessment of treatment response.



Please follow us on Twitter



@ATS_RSJ

and like our Facebook



page!

If you or someone you know would like to be featured as an ATS RSF ECP please email Katrina Tonga (katrina.tonga@sydney.edu.au)